

PHYSIOMATTERS PRESENTS

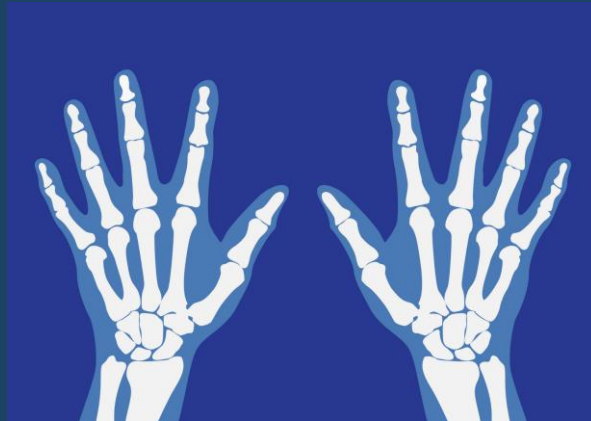
THERAPY
LIVE 

Upper Limb – Rheumatology Reasoning



RHEUMATOLOGY.PHYSIO

ONLINE.



Jack March | Rheumatology.Physio

Who am I?



Other Resources



RHEUMATOLOGY.PHYSIO

ONLINE.

Rheumatology

AT A GLANCE



A QUICK REFERENCE GUIDE TO:

- Axial Spondyloarthritis
- Lupus
- Osteoporosis
- Rheumatoid Arthritis
- Gout
- And More...

Jack March | Rheumatology.Physio

The Hand

AT A GLANCE



A QUICK REFERENCE GUIDE TO:

- Basal Thumb Arthritis
- De Quervain's Tenosynovitis
- Intersection Syndrome
- Cubital Tunnel Syndrome
- And More...

Debs Stanton

Spinal Masqueraders

AT A GLANCE



A QUICK REFERENCE GUIDE TO:

- Cauda Equina Syndrome
- Metastatic Spinal Cord Compression
- Spinal Fracture
- Spinal Infection
- And More...

Andrew Cuff



RHEUMATOLOGY.PHYSIO

ONLINE.

RHEUMATOLOGY.PHYSIO

Jack March | Rheumatology.Physio

Why Rheum?



Jack March | Rheumatology.Physio

Case



35 year old male – Right hand pain

Observations – high BMI, walks with a limp into clinic.

Story



Hand started hurting after a weekend of painting walls, has been variable since, pain is located in right wrist, index and middle fingers.

Not sure but thinks he has had some swelling in his wrist. Its annoying him because its his dominant hand and it just isn't as flexible as he wants it to be.

Tends to not be too bad working at his computer but gets stiff driving and after watching tv in the evenings.

What Jumps Out



Hand started hurting after a weekend of painting walls, has been variable since, pain is located in right wrist, index and middle fingers.

Not sure but thinks he has had some **swelling** in his wrist. Its annoying him because its his dominant hand and it just isn't as flexible as he wants it to be.

Tends to not be too bad working at his computer but gets **stiff** driving and after watching tv in the evenings.

Case



RHEUMATOLOGY.PHYSIO

ONLINE.

Jack March | Rheumatology.Physio

Follow the narrative



“Elaborate more on why its annoying you/the lack of flexibility”

Take first thing in the morning, it takes ages to stop being stiff, I cant grip things so its hard to dress / eat / drink

“How long does that last?” About an hour, using the hand improves things and the ibuprofen has kicked in.

“Tell me about the rest of the day” its ok the rest of the day unless its really still like after driving then its stiff and painful again. It doesn't bother me at night.

Case



RHEUMATOLOGY.PHYSIO

ONLINE.

Jack March | Rheumatology.Physio

General health screening



General health screening

THREADS – nil relevant.

How is your sleep – normal

DH – ibuprofen

General health screening



General health screening

THREADS – nil relevant.

How is your sleep – normal

DH – ibuprofen

Any problems with skin – yes psoriasis

Stomach / bowels? No but dad has ulcerative colitis

Eyes? No

SCREEND'EM BEFORE YOU TREAT'EM

A clinical tool to help identify spondyloarthritis (SpA) in patients with tendinopathy.

SKIN

6-42% of patients with psoriasis develop psoriatic arthritis.



COLITIS OR CHROHN'S

Arthritis is one of the most common extra-intestinal manifestations of inflammatory bowel disease. The prevalence of SpA in patients with Crohn's is estimated to be 26% at 6 year follow up.



RELATIVES

There is a strong relationship between SpA and HLA-B27 positive patients.

Family members of patients with SpA who are HLA-B27 positive have a 16-fold increase chance of developing ankylosing spondylitis if they are also HLA-B27 positive.



EYES

Acute anterior uveitis (AAU) can cause a painful, red eye with photophobia and blurred vision. 40% of patients presenting with idiopathic AAU have undiagnosed SpA. 50% of patients with AAU are HLA-B27 positive and >50% of these have SpA.



EARLY MORNING STIFFNESS

Inactivity related stiffness that lasts for more than 30 minutes is suggestive of inflammatory disease.

NAILS

Nail lesions occur in 87% of SpA patients and include:

- small depressions in the nail (pitting)
- thickening of the nails
- painless detachment from the nail bed (onycholysis).



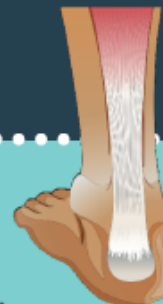DACTYLITIS

Sausage like swelling of the digits is a hallmark sign of psoriatic arthritis, occurring in 50% of cases.



ENTHESITIS

98% of SpA patients have at least one abnormal enthesis. The most common sites are the Achilles tendon, plantar fascia and patellar tendon.



MOVEMENT & MEDICATION EFFECT

SpA patients report improvement with activity but not with rest, and a favourable response to NSAIDs.

Created by
Paul Kirwan



ISBN/EAN: 978-90-75823-92-9, d18 page 32



designed by freeplk.com



RHEUMATOLOGY.PHYSIO
ONLINE.

Thanks to:
Paul Kirwan
@pdkirwan

Case

Stay Vigilant
Screen(DEM)



PHYSIOMATTERS PRESENTS

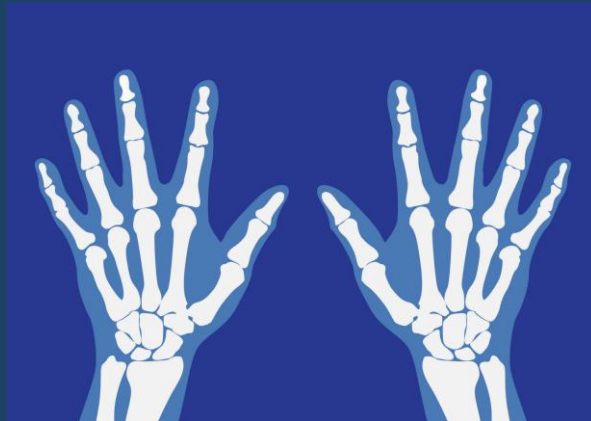
THERAPY
LIVE 

Upper Limb – Rheumatology Reasoning



RHEUMATOLOGY.PHYSIO

ONLINE.



Jack March | Rheumatology.Physio